



SCUOLA INTERNAZIONALE SUPERIORE DI STUDI AVANZATI

SISSA Digital Library

Effect of body-part specificity and meaning in gesture imitation in left hemisphere stroke patients

Original

Effect of body-part specificity and meaning in gesture imitation in left hemisphere stroke patients / Tessari, A.; Mengotti, P.; Faccioli, L.; Tuozi, G.; Boscarato, S.; Taricco, M.; Rumiati, R. I.. - In: NEUROPSYCHOLOGIA. - ISSN 0028-3932. - 151:(2021). [10.1016/j.neuropsychologia.2020.107720]

Availability:

This version is available at: 20.500.11767/127831 since: 2024-12-18T18:17:01Z

Publisher:

Published

DOI:10.1016/j.neuropsychologia.2020.107720

Terms of use:

Testo definito dall'ateneo relativo alle clausole di concessione d'uso


Publisher copyright

Elsevier

This version is available for education and non-commercial purposes.

note finali coverpage

(Article begins on next page)



Effect of body-part specificity and meaning in gesture imitation in left hemisphere stroke patients

Alessia Tessari^{a,*}, Paola Mengotti^b, Luca Faccioli^c, Giovanni Tuozi^{a,d}, Silvia Boscarato^c, Mariangela Taricco^c, Raffaella I. Rumiati^{e,f}

^a Department of Psychology, University of Bologna, Bologna, Italy

^b Cognitive Neuroscience, Institute of Neuroscience & Medicine (INM-3), Forschungszentrum Jülich, 52425, Jülich, Germany

^c University Hospital Policlinico Sant'Orsola Malpighi, Bologna, Italy

^d Department for Life Quality Studies, University of Bologna, Bologna, Italy

^e Area of Neuroscience, SISSA, Trieste, Italy

^f SSAS - La Sapienza, Rome, Italy

ARTICLE INFO

Keywords

Apraxia
Imitation
Left brain-damage
Body
Finger gestures
Meaning

ABSTRACT

Previous studies showed that imitation of finger and hand/arm gestures could be differentially impaired after brain damage. However, so far, the interaction between gesture meaning and body part in imitation deficits has not been fully assessed. In the present study, we aimed at filling this gap by testing 36 unilateral left brain-damaged patients with and without apraxia (20 apraxics), and 29 healthy controls on an imitation task of either finger or hand/arm meaningful (MF) gestures and meaningless (ML) movements, using a large sample of stimuli and controlling for the composition of the experimental list. Left-brain damaged patients imitated ML finger worse than hand/arm movements, whereas they did not show the same difference in MF gesture imitation. In addition, apraxic patients imitated finger movements worse than hand/arm movements. Furthermore, apraxic patients' imitation performance was equally affected irrespective of the action meaning, whereas non-apraxic patients showed better imitation performance on MF gestures. Results suggest that MF gestures are processed as a whole, as imitation of these gestures relies on the stored motor programs in long-term memory, independently of the body part involved. In contrast, ML movements seem to be processed through direct visuo-motor transformations, with left-brain damage specifically disrupting imitation performance of the more cognitive demanding finger movements.

1. Introduction

Imitation is a fundamental ability that allows individuals to efficiently acquire a wide range of movements by observing a demonstrator performing them. The tendency to imitate has been extensively studied in children (e.g., Ray and Heyes, 2011) and adults (e.g., Rumiati and Bekkering, 2003), as well as in monkeys and great apes (e.g., Tomasello et al., 1993). This ability can be selectively impaired after brain damage giving rise to a syndrome clinically called ideomotor apraxia. Ideomotor apraxia has been defined as a deficit in the intentional execution of gestures that cannot be explained as being due to simple motor or sensorial deficits, to comprehension deficits, object recognition problems or frontal inertia (see De Renzi and Faglioni, 1999). Rothi, Ochipa and Heilman (1991) proposed the first cognitive model of gesture recognition and production that distinguished between input and output processes, between different types of stimulus (gesture or object), and different modalities in which gestures and objects are presented (verbal vs. visual). As far as imitation is concerned, the original model by Rothi et al. (1991), as well as its following evolutions (e.g., Cubelli et al., 2000; Rumiati and Tessari, 2002; Buxbaum and Randerath, 2018), hypothesized the existence of two separate processes for

transforming the visual input (i.e., the seen gesture as shown by the demonstrator) into a motor act (i.e., the imitated movement): the semantic and the direct route. After the first common stage, during which a movement is analysed, one of the two routes is selected depending on whether the movement is already known or not. The semantic route is selected for known, meaningful (MF) gestures that already belong to a person's repertoire, and that are stored in the semantic long-term memory (LTM). The direct route is selected when a new, meaningless (ML) movement is presented, as no matching representation can be found in the semantic memory. This mechanism allows converting any visually presented movement, including MF gestures, into motor output, by parsing it in smaller and simpler motor components. The outcome of this visuomotor transformation is then briefly kept in the motor short-term/working memory (WM) system (hypothesized by Cubelli et al., 2000, and empirically confirmed by Rumiati and Tessari, 2002; see also Buxbaum and Randerath, 2018). The motor WM system is common to the direct and semantic route and allows learning new actions. See Fig. 1.

Evidence for the existence of these putative two routes in imitation comes from several neuropsychological studies with brain-damaged patients (e.g., Bartolo et al., 2001; Cubelli et al., 2000; Goldenberg and Hag-

* Corresponding author.

E-mail address: alessia.tessari@unibo.it (A. Tessari)

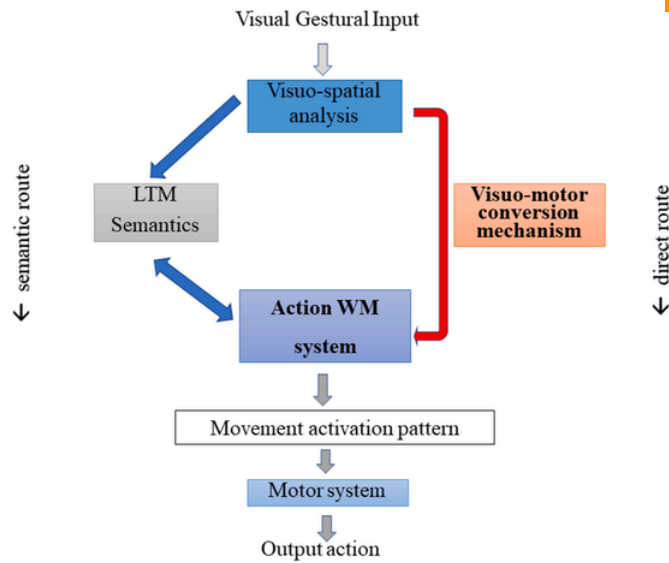


Fig. 1. A modified version of the model originally proposed by Tessari et al. (2007). The model includes two routes involved in the imitation of meaningful (MF) and meaningless (ML) gestures. After the first common visuo-spatial analysis is performed, if the action to be imitated is ML, then the direct route is selected, whereas if the action is MF, then the semantic route is preferably selected (although the direct route can also be used). The motor short-term/working memory subsystem is common to both the semantic and direct route, and it is essential for motor learning. LTM: long term memory; WM: working memory.

mann, 1997; Mengotti et al., 2013; Tessari, Canessa, Ukmar e Rumiati, 2007), as well as from experimental studies on healthy adults (e.g., Carmo and Rumiati, 2009; Rumiati and Tessari, 2002; Tessari and Rumiati, 2004; Tessari et al., 2006) and children (Sebastianutto et al., 2017). In particular, double dissociating cases of patients with selective deficits in imitating either MF gestures or ML movements were documented (Bartolo et al., 2001; Mengotti et al., 2013; Tessari et al., 2007), thus providing causal evidence in support of the relative independence of the two routes.

Interestingly, these dissociations between patients emerged when MF gestures and ML movements were presented in separate lists. The list-composition effect was described first by Tessari and Rumiati (2004) in healthy individuals, using particular experimental manipulations of stimulus presentation, and later replicated in many other studies (Cubelli et al., 2006; Rumiati et al., 2005; Tessari et al., 2007; Carmo and Rumiati, 2009; Press and Heyes, 2008). More specifically, when MF gestures and ML movements are intermingled, the direct route is selected to imitate both types of stimuli, and no difference emerges in imitation performance between the two. However, when the two types of stimuli are presented in separate lists, the semantic route predominates for imitating MF gestures and the direct route for imitating the ML movements (Cubelli et al., 2000; Tessari & Cubelli, 2014; Tessari and Rumiati, 2004; Tessari et al., 2007). Indeed, in neuropsychological studies in which the mixed presentation of MF and ML stimuli was used, no dissociations between the two were reported (e.g., Achilles et al., 2016; Achilles et al., 2019; Hoeren et al., 2014; Toraldo et al., 2001).

The imitation deficits have been associated with lesions of the left inferior parietal lobe and its underlying white matter, the premotor cortex (e.g., Basso et al., 1980; Dressing et al., 2018; Geshwind, 1965; Goldenberg and Randerath, 2015; Rothi and Heilmann, 1985; Rothi et al., 1991; Sirigu et al., 1995; Tessari et al., 2007; Weiss et al., 2008), and the basal ganglia and thalamus (see Leiguarda, 2001); for a review). Moreover, when the meaning of the stimuli was considered, the imitation of MF gestures and ML movements revealed a certain degree of overlap in inferior parietal regions, but also discrete neural correlates for the two stimulus types (see Achilles et al., 2016; Achilles et al., 2019; Bartolo et al., 2001; Goldenberg and Hagmann, 1997; Hoeren et al., 2014;

Andrei a capo qui ("in particular"), iniziando un nuovo paragrafo, e continuerei nello stesso paragrafo per la frase successiva ("however"), non andando a capo

xxx-xxx

Mengotti et al., 2013; Rumiati et al., 2005; Peigneux et al., 2004; Tessari et al., 2007). **In particular**, the direct route that processes ML movements, has been associated with more dorsal or posterior parietal regions, within the dorso-dorsal stream (see Binkofski and Buxbaum, 2013, for a review; Hoeren et al., 2014; (Martin et al., 2016, 2017); (Rumiati et al., 2005)).

However, the semantic route processing MF gestures has been associated with regions within both the ventral stream, encompassing the posterior/superior portion and the anterior portion of the temporal lobe, and the ventro-dorsal stream, including the ventral part of the inferior parietal cortex (Hoeren et al., 2014; (Martin et al., 2016, 2017); Rijnters, Weiller, Bormann & Musso, 2012; (Rumiati et al., 2005); Tessari et al., 2007; Weiller et al., 2009; Weiller et al., 2011). The ventral stream is mainly involved in decoding the meaning of a movement and it plays an important role in processing MF intransitive gestures; on the other hand, the ventro-dorsal stream seems to store gesture "engrams", and it is supposed to process mainly tool-related, transitive MF gestures (Dressing et al., 2018). However, there is some evidence that the ventro-dorsal stream might also support imitation of ML movements (i.e., Buxbaum et al., 2014; Mengotti et al., 2013; Tessari et al., 2007).

Action imitation is influenced not only by the meaning of the gesture but also by the body-part that performs it. In particular, a distinction has been made between imitation of finger gestures and imitation of hand/arm gestures, reflecting grasping and reaching, respectively. Neuropsychological studies have long shown that these two motor components, although usually interacting, are relatively independent and can be selectively affected by brain lesions (e.g., Jeannerod et al., 1994; Shallice et al., 2005; Sirigu et al., 1991; Poizner et al., 1990). In particular, a double dissociation in apraxic patients making perseverative errors when pantomiming object use or using them, with either the arm or the hand, was also documented (Shallice et al., 2005). As regards the anatomical substrates, in several studies imitation of ML finger and hand/arm configurations, and sometimes also of MF gestures, was found to be associated with different brain regions depending on the body parts involved in the gestures (Goldenberg and Hagmann, 1997; Goldenberg, 1999, 2001; Goldenberg and Strauss, 2002; Goldenberg and Karnath, 2006). For example, Goldenberg and Karnath (2006) found a behavioural double dissociation between hand and finger imitation, associated with an anatomical anterior (finger)/posterior (hand) dissociation in left brain-damaged patients. Lesions including the inferior frontal operculum generated impairments in imitation of ML finger gestures, while posterior lesions, particularly the posterior parietal lobule, led to impairments in imitation of hand/arm postures (see Dovern et al., 2011, (Tanaka and Inui, 2002); Tanaka et al., 2001, for similar results). However, other studies led to different results: a study on a larger sample of patients with left hemisphere lesions did not confirm such an anterior/posterior dissociation but reported an association between the dorso-dorsal stream, in particular, the inferior and superior parietal lobe, and the overall ability to imitate ML finger and arm/hand of gestures (Hoeren et al., 2014). Also, Achilles and colleagues (Achilles et al., 2017) investigated the effect of body part (hand/arm vs. finger) only in ML movement imitation in a large sample of patients. They found that hand and finger ML movements share similar neural circuits in the left hemisphere and did not find the double dissociation between hand/arm and finger imitation reported in other studies (e.g., Dovern et al., 2011; Goldenberg and Strauss, 2002; Goldenberg and Karnath, 2006). Thus, nowadays a study investigating all possible combinations of gesture meaning (MF vs. ML) and body part (finger vs hand/arm) is still needed.

On ("depending" on the body part involved) left brain-damaged patients, we tested whether different neuropsychological patterns would emerge depending on not only the meaning of intransitive gestures to be imitated but also to the body part involved (finger vs. hand/arm component). At variance with the studies mentioned above, we employed all possible combinations of the factors affecting imitation: gesture meaning and body part involved in gesture imitation (i.e., both MF and ML gestures involving either fingers and

hand/arm). Indeed, previous studies reported differences in imitation processing between finger and hand ML movements (Goldenberg and Karnath, 2006; Achilles et al., 2017), or between MF gestures and ML finger movements (Achilles et al., 2016, 2019). Given the confound effects discussed above, **we also controlled for the list composition**. Moreover, a large sample of MF and ML finger and hand/arm gestures was used in order to overcome a shortcoming of previous studies (see Achilles et al., 2016's criticism).

We predicted that the body part involved in the gesture should differentially influence the imitation of MF and ML gestures. A gradient of complexity might emerge between imitation of ML finger and hand/arm gestures, with the former being more difficult to imitate than the latter. Finger gestures seem to be characterized by a greater biomechanical complexity than hand/arm gestures, requiring higher demands on movements precision in configuring all individual fingers (as also suggested by Achilles et al., 2019). On the contrary, MF gestures, being already known, should be recalled as a single chunk from LTM. Therefore finger and hand/arm MF gestures should be imitated to the same extent independently of the body part involved or the gesture complexity.

2. Methods

2.1. Participants

Patients. A group of 36 patients with left hemisphere damage (12 females) took part in the study (mean age = 69.53, SD = 12.24; mean education = 10.03, SD = 4.38; mean months from onset = 2.2, SD = 1.16). They were recruited in the rehabilitation ward of "Sant'Orsola Malpighi" hospital in Bologna and the rehabilitation and neurological unit of "Ospedali Riuniti" hospital in Trieste. The inclusion criteria were the following: having a single focal unilateral left-hemispheric lesion, according to clinical information and CT or MRI scans; being physically able to complete the experiment; having no history of alcohol or other substance abuse; being younger than 90 years; having at least 3-years of education. All patients suffered from a stroke and were all tested in their chronic state from one to five months from illness onset. The demographic variables are summarized in Table 1. All patients underwent a neuropsychological evaluation in order to assess general intelligence, language functions, executive functions, memory, visuo-spatial and attentional abilities. See Table 2 for details.

Twenty patients were apraxic to two tests for the diagnosis of ideomotor apraxia: De Renzi et al.'s test (De Renzi, Motti & Nichelli, 1980; requiring imitation of mixed MF intransitive gestures and ML movements) and STIMA (Tessari et al., 2015; based on the presentation of separated lists of intransitive MF gestures and ML movements). There was a very high agreement between the results at the two tests (Cohen's kappa = 0.888).

As tool use was not assessed, the diagnosis of apraxia was based on performance in imitation of intransitive gestures and meaningless movements, clinically referred to as ideomotor apraxia.

Controls. Twenty-nine healthy adults (16 females) served as a control group for the imitation task. The two groups did not differ from the **Mi pareva che avessi aggiunto le info di table 1 nel testo in modo da togliere la tabella. O ricordo male? Qui c'e' ancora** patients'

Table 1

The demographic variables of all participants (patients and healthy controls) who took part in the study are presented. In the bottom line, *t*-test comparisons are reported for age and education.

	N	Education		♂	♀	Age	
		Mean	SD			Mean	SD
LBD patients	36	10.07	4.40	24	12	69.97	12.16
Controls	29	10.32	3.74	13	16	64.59	10.64
		<i>t</i> (65) = 0.252, <i>p</i> > 0.05				<i>t</i> (65) = 1.124, <i>p</i> > 0.05	

group for demographic variables (i.e., age, education and gender; independent-samples *t*-tests, All *P*s > 0.05).

All participants gave informed consent according to the Declaration of Helsinki. The study was approved by the Ethics Committees of Sant'Orsola-Malpighi Hospital and SISSA.

2.2. Stimuli and procedure

The experimental task consisted in an imitation task of finger and hand/arm gestures controlled for meaning (both MF and ML gestures). Eighteen known, intransitive (i.e., symbolic) unilateral MF gestures and 18 new, unrecognizable ML movements, matched for complexity with the MF ones were used as stimuli. The gestures are taken from a controlled set of gestures used in previous research (Bonivento et al., 2013; Carmo and Rumiati, 2009; Mengotti et al., 2015; Mengotti et al., 2013; Tessari et al., 2015; see Appendix 1). Half of both MF and ML gestures involved movements mainly performed with the fingers (i.e., distal movements, for example, the OK gesture). The remaining half gestures involved movements primarily performed with the hand/arm (e.g., the military salute). MF and ML gestures were presented in two consecutive but separate blocks: the MF gestures block was presented first, in order to prevent the patients from selecting the direct route to imitate both types of gestures. Indeed, if the ML gesture block were presented first, this might trigger the selection of the direct route to imitate them and, by inertia, continue to imitate the MF actions using this route, instead of the semantic route. The order in which MF and ML gestures are presented in an imitation task has been proved to be very important in highlighting specific deficits of the semantic and the direct routes (Cubelli et al., 2006; Tessari and Cubelli, 2014; Tessari and Rumiati, 2004; Tessari et al., 2007).

Based on previous studies (e.g., Carmo and Rumiati, 2009; Tessari and Rumiati, 2004), an action was considered incorrect if it involved one of the following errors:

- 1) Spatial error: the overall movement is correct, but the hand or the arm posture are moved along the wrong direction, or the wrong plane, or the movement endpoint is not reproduced correctly;
- 2) Visual error: the patient reproduces a movement that is visually similar to the shown one, but it is not included in the list, or she/he merges two gestures included in the list;
- 3) Omission: the patient does not reproduce any gesture;
- 4) Unrecognizable gesture: the patient produces a movement that the experimenter does not recognize.

An imitated action was scored 0 if the imitation contained a mistake and 1 if it was correctly imitated. The maximum score of the imitation test is 36: 9 for finger MF gestures and, 9 for hand/arm MF gestures (18 total MF gestures); 9 for finger ML movements, and 9 for hand/arm ML movements (18 total ML movements). The raw scores of the imitation test for each condition are reported in Table 2.

The experimenter sat in front of the patient and performed the gestures with the same ipsilesional limb that the patient could use for imitation in a mirror configuration. **Togliere "the". Only "at ceiling"**

At the end of the imitation test, patients were required to recognize the previously presented MF gestures to assess whether their semantics was intact or not. All patients performed at **the ceiling** in the MF gestures recognition.

2.3. Lesion analyses

CT or MRI scans were available for 30 of the 36 patients included in the study; therefore, lesion analyses were performed on this number of patients. An experienced neuroradiologist (L.F.), blind to the hypotheses of the study, mapped the lesioned areas of each patient onto the normalized MNI tem-

nel Raven tutti gli scores sono in grassetto, e' un errore nel file che hai mandato a loro, controlla la versione precedente della tabella

Table 2
The table consists of two main sections: a) The neuropsychological assessment ; b) Raw scores of the experimental imitation task (maximum score = 9).

Neuropsychological testing														Imitation			
Token Test	Naming	LTM (Prose)	LTM (Rey's Figure)	STM (Corsi)	STM (Span fwd)	WM (Span bwd)	Raven	Weigl	TMT A	TMT B	VOSP shape detection	VOSP object decision	IMA (STIMA)	MF		ML	
														finger	arm	finger	arm
C1	n.a	n.a	n.a	4.25	4.75	3.21	33.8	11.75	24	236	20	15	68	8	9	7	9
C2	50*	15.00	n.a	5.25	6.75	5.08	33.1	10	35	95	20	15	70	9	9	9	8
C3	36*	15	n.a	2.25	t.i.	n.a.	21.2	7.25	t.i.	t.i.	14	16	54	6	7	5	7
C4	50*	0	n.a	n.a	t.i.	n.a.	20.8	1.5	194	t.i.	19	12	37	2	4	3	6
C5	9*	109	n.a.	5.25	5	n.a.	27.5	11	35	t.i.	20	18	31	3	2	2	6
C6	36*	17	n.a	3.5	n.a	n.a.	34.3	5	59	179	20	18	39	6	5	2	6
C7	14*	102	n.a	3.25	t.i.	n.a.	21.2	7.25	t.i.	t.i.	14	16	49	4	5	6	7
C8	25*	83	n.a	4.5	4	n.a	31	6.5	48	76	20	16	44	4	5	4	6
C9	18*	112	n.a	2	4.25	3.39	28.3	10.25	90	452	18	19	48	5	2	6	8
C10	20*	100	9.6	4	4.25	5.28	27	6.75	210	752	20	15	61	8	6	5	8
C11	50*	n.a.	n.a	4.5	n.a.	n.a.	29.8	9.75	36	189	20	17	56	7	5	8	8
C12	28*	107	12.05	4	4.25	3.52	16.3	9.25	179	332	20	16	69	9	8	8	8
C13	24*	96	10.85	4	6.25	2.52	24.3	5.25	102	262	20	16	42	3	4	1	8
C14	5*	102	n.a	4.5	4	3	33.4	12.5	33	340	19	19	68	9	9	8	8
C15	n.a	n.a	n.a	'	3	n.a.	19.5	2	303	t.i.	19	n.a.	53	3	6	7	6
C16	47*	118	11.05	3.75	4	2.1	23.8	10.25	44	212	18	11	52	4	6	6	8
C17	42*	90	6.5	5	3.5	3.87	33.4	9.5	41	194	20	18	72	9	9	9	9
C18	n.a	n.a	n.a	3.75	4.5	n.a	29.6	5.75	n.a	n.a	20	18	68	8	8	9	8
C19	30*	110	13.5	3	3.5	3.52	30.9	5.75	110	415	16	18	65	8	8	8	7
C20	22*	25	n.a	2.75	3.75	2.5	19.6	1.75	29	201	20	16	72	9	9	9	9
C21	43*	108	10.9	5.25	4.5	2.93	30	16.5	46	244	19	16	71	9	8	9	9
C22	n.a	86	n.a	n.a	3.5	2	23	3.25	37	138	19	15	40	2	5	3	5
C23	n.a	n.a	n.a	5.25	4.5	n.a	32.3	n.a	n.a	64	20	19	53	5	7	3	7
C24	34*	23	n.a	5.25	4.75	n.a	35.2	n.a	questo dovrebbe essere solo t.i.	9	n.a	n.a	42	1	5	3	8
C25	30*	79	11.6	4.25	4	3.13	24	5	211	427	20	19	53	7	4	4	9
C26	30*	84	n.a	n.a	2	n.a	21.4	3.25	t.i.b	t.i.b	19	13	65	8	9	6	8
C27	34	53	0.5	4.5	3.25	2.68	26.1	3	175	336	20	20	61	8	7	7	7
C28	31*	87	n.a	n.a	n.a	n.a	31.1	9	n.a	4	20	17	54	8	6	5	6
C29	14*	21	n.a	4.25	n.a	n.a	30.4	3.25	172	NA	20	15	65	9	8	6	7
C30	31*	88	n.a	5.25	6.5	6.84	31.5	9	n.a	t.i	19	17	64	9	7	7	7
C31	47*	118	0.00	4.25	4	2.37	18.5	12.50	238	545	20	14	63	8	7	7	8
C32	t.i.	t.i.	n.a	6.25	'	n.a.	32.8	8	94	t.i.	20	13	65	8	9	7	7
C33	37*	70	0.75	3.5	1.25	0.89	28.1	1	393	559	15	12	32	0	0	6	5
C34	33*	58	8.5	4	5.25	3.28	26	8	195	456	18	16	50	8	6	5	4
C34	30*	93	n.a	4.5	n.a	n.a	32	n.a	147	313	19	17	58	8	6	6	8
C36	30*	60	n.a	3	n.a	n.a	33.3	9	n.a	n.a	18	17	58	7	7	5	7

plate using MRIcron (<https://www.nitrc.org/projects/mricron>; Rorden et al., 2007).

We first inspected our sample by overlaying the lesions of the left brain-damaged patients, thus creating a map of the regions more often lesioned. We then analysed our lesion data adopting the subtraction approach (Rorden and Karnath, 2004). Using MRIcroN, the lesions of all patients with defective performance, on the one hand, and those of all patients with normal performance on the other hand, were overlapped separately for each condition. Patients' performance was considered defective or within normal range based on individual *t*-scores, calculated with the software Singlims_ES (http://homepages.abdn.ac.uk/j.crawford/pages/dept/Single_Case_Effect_Sizes.htm) following the approach described in Crawford and Garthwaite (2005). Data for each participant and for the control group of healthy participants were entered as raw scores. The software provides a *t*-score for each individual performance and estimates the abnormality of the individual score with respect to the mean performance of the corresponding control sample. Subsequently, the overlap of the group showing no deficit in the condition of interest was subtracted from the overlap of the patients that presented a deficit in that condition. The lesion map generated by the subtraction highlights only the regions that are functionally involved in the task, independently of the anatomical vulnerability of the regions. Even if the subtraction approach is more reliable than simple overlap in highlighting lesioned regions underlying the deficit (and not only the more frequently lesioned regions), it is still a descriptive method that does not allow for statistical inference (de Haan and Karnath, 2018).

We first produced subtraction maps of lesioned regions associated with a deficit in imitating overall MF gestures and ML movements and, secondly, more specific maps for finger and hand/arm imitation separately for the two stimulus types. Only regions lesioned in at least 40% of the patients are described and shown, with the exception of the finger ML movements imitation, which are reported at a less restrictive threshold of 25% of patients with a lesion.

3. Results

3.1. Behavioural results

Overall the group of healthy controls performed better than the patients in the imitation task (independent samples *t*-test, $t(63) = 5.38$, $p < 0.001$; controls' mean = 33.10, SE = 0.41, and patients' mean = 25.80, SE = 1.17). Healthy controls showed significant differences neither between imitation of MF finger vs. MF hand/arm gestures ($t(28) = 0.81$, $p = 0.42$) nor between ML finger vs. ML hand/arm movements ($t(28) = 1.62$, $p = 0.12$).

We then proceeded analysing only the patients' group by comparing apraxic and non-apraxic patients. The mixed ANOVA on imitation scores included the following factors: Gesture type (MF vs. ML gestures), Body component (fingers vs. hand/arm) as within-subjects factors, and Apraxia (apraxic patients vs. non-apraxic patients) as a between-subjects factor.

The Gesture type x Body component interaction was significant ($F(1,34) = 11.87$, $p = 0.001$, $\eta^2 = 0.19$; See Fig. 2): Finger movements were imitated to the same extent of hand/arm movements when MF gestures were shown (two tailed *t*-test with Bonferroni correction, $t(35) = 0.195$, $p = 0.846$; mean MF finger movements = 6.57, SE = 0.31 and mean MF hand/arm movements = 6.49, SE = 0.25), while ML gestures showed a sig-

nificant difference, with hand/arm movements better imitated than finger ones (two tailed *t*-test with Bonferroni correction, $t(35) = 4.27$, $p < 0.001$; mean ML finger movements = 6.03 SE = 0.27 and mean ML hand/arm movements = 7.34, SE = 0.18); Gesture type x Apraxia ($F(1,34) = 8.12$, $p = 0.007$; $\eta^2 = 0.19$) and Body component x Apraxia ($F(1,34) = 8.06$, $p = 0.008$, $\eta^2 = 0.19$) interactions were also significant. Apraxic patients imitated MF and ML gestures to the same extent ($t(19) = 2.05$, $p = 0.055$; mean MF gestures = 4.25, SE = 0.32 and mean ML gestures = 5.62, SE = 0.24), whereas non-apraxic patients imitated MF better than ML gestures ($t(15) = 3.91$, $p = 0.006$; mean MF gestures = 8.31, SE = 0.36 and mean ML gestures = 7.75, SE = 0.26). Non-apraxic patients imitated both finger and hand/arm gestures at the same extent ($t(15) = 0.00$, $p = 1$), but apraxic patients showed a difference between the two body components ($t(19) = 3.42$, $p = 0.003$), with less accurate performance on finger gestures (mean = 4.57, SE = 0.31) than hand/arm ones (mean = 5.80, SE = 0.22).

Moreover, the main factors Body component and Apraxia were significant. Overall, hand/arm gestures were better imitated than the finger ones ($F(1,34) = 8.06$, $p = 0.008$, $\eta^2 = 0.19$; finger gestures = 6.30, SE = 0.23, and hand/arm gestures = 6.92, SE = 0.17), and non-apraxic patients imitated more gestures than the apraxic ones ($F(1,34) = 68.66$, $p < 0.001$, $\eta^2 = 0.67$; mean apraxic patients = 5.19, SE = 0.23 and mean non-apraxic patients = 8.03, SE = 0.26). The Gesture type factor was not significant.

3.2. Lesion analysis

We first inspected our sample by overlaying the lesions of the left brain-damaged patients, thus creating a map of the regions more often lesioned (see Fig. 3).

Then, we performed a subtraction analysis for each stimulus type, first distinguishing the stimuli according to their meaning (MF vs. ML) and, secondly, distinguishing them according to the effector used to imitate (finger vs. hand/arm), separately for MF and ML gestures. We subtracted the lesioned regions of patients without an imitation deficit in that specific type of gesture (no-deficit group) from the lesioned regions of the patients that showed a deficit in imitation of the respective type of gesture, as established on the basis of the *t*-scores calculated on individual patients' performance (see Methods).

Lesions in patients with impaired imitation of MF gestures, after subtracting the lesions of the no-deficit group, involved mainly the inferior parietal lobe, including supramarginal and angular gyri, parietal operculum and the posterior part of the superior and middle temporal gyri. In contrast, lesions in patients with impaired imitation of ML movements, after subtracting the lesions of the no-deficit group, involved mainly inferior frontal regions, including small parts of the inferior frontal gyrus, central and frontal operculum, but also a small part of the supramarginal gyrus, overlapping with the correlates of MF gestures imitation (see Fig. 4A).

Within MF gestures, regions lesioned in patients with impaired imitation in finger gestures, after subtracting the lesions of the no-deficit group, were mainly located in the superior temporal gyrus, the planum temporale, the parietal operculum, the supramarginal and angular gyri. Again, within MF gestures, regions lesioned in patients with impaired imitation in hand/arm gestures, after subtracting the lesions of the no-deficit group, were mainly located in the middle temporal gyrus, the planum temporale, the parietal operculum, the temporo-occipital junction, the supramarginal and angular gyri (see Fig. 4B). Within ML movements, regions lesioned in patients with impaired imitation in finger movements, after subtracting the lesions of the no-deficit group (using a less restrictive threshold of percentage of patients lesioned), were mainly located in the middle temporal gyrus, the temporo-occipital junction, and the lateral occipital cortex. In contrast, the regions lesioned in patients with impaired imitation in hand/arm movements, after subtracting the lesions of the no-deficit group, were mainly located in the inferior frontal, supramarginal and angular gyri (see Fig. 4C). In addition, small clusters both for finger and hand/arm ML movements were located in

¹ Standardized neuropsychological tests used to assess: general intelligence (Raven Progressive Matrices PM47, Carlesimo et al., 1996), language functions (Comprehension: *Token test, Spinnler and Tognoni, 1987; ° AAT Token test; Production: AAT, naming test Luzzatti et al., 1996), executive functions (Trail Making Test, part B; Giovagnoli et al., 1996; Weigl's sorting test; Spinnler and Tognoni, 1987), memory (15 words memory test, Rey, 1964; Corsi spatial short-term memory, Spinnler and Tognoni, 1987; digit span for verbal short-term memory digit, Orsini et al., 1987), visuo-spatial (VOSP, Visual Object and Space Perception battery; shape detection and shape decision; Warrington and James, 1991), and attentional (Trail Making Test, part A; Giovagnoli et al., 1996) abilities. "t.i.": test interrupted because the patient was not able to perform the task. "n.a.": test not administered. °Deficit due to neglect. Pathological scores are reported

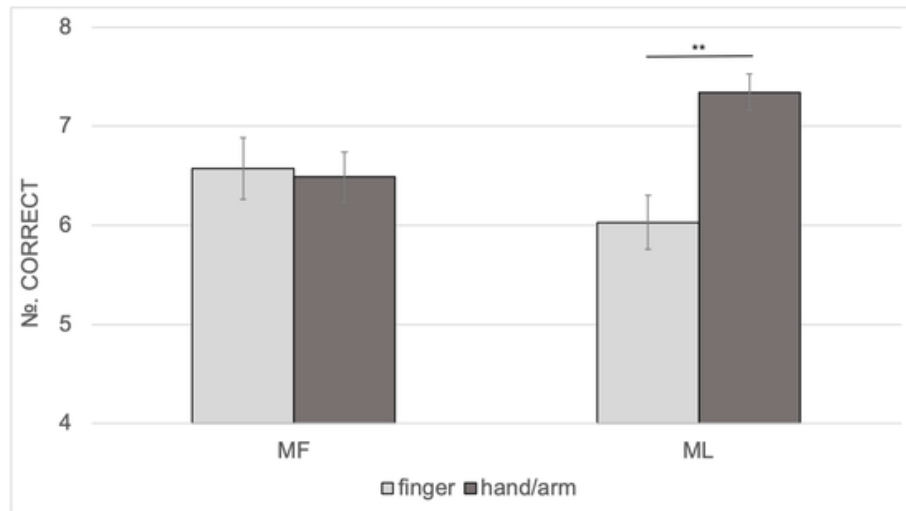


Fig. 2. The two-way Gesture type \times Meaning interaction performed on patients' data (both apraxic and non-apraxic patients) is displayed. Average scores of correctly imitated actions are presented for both meaningful (MF) and meaningless (ML) gestures according to the involved body district. Error bars represent the standard error of the mean.

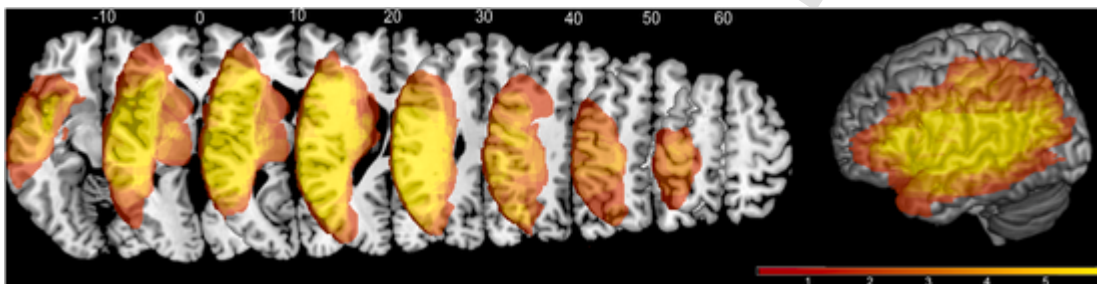


Fig. 3. Results of the lesions overlap for all patients.

Lamentarsi dei bordi in figura

Qui forse andrei a capo

inferior frontal regions, involving, in particular, the insular cortex for finger and the inferior frontal gyrus for hand/arm ML movements.

4. Discussion

In this study, for the first time, the imitation of either finger or hand/arm components of both MF and ML gestures was compared and analysed. In particular, this is the first study to investigate the difference between finger and hand/arm in MF gestures, as previous studies investigated this aspect only in ML gestures (e.g., Goldenberg and Karnath, 2006; Achilles et al., 2017) or restricted their investigation to MF and ML finger gestures (Achilles et al., 2016, 2019).

We tested whether different neuropsychological patterns emerge in left brain-damaged patients, according to not only the meaning of the gesture but also the body parts involved (i.e., fingers vs. hand/arm). Indeed, we predicted a different pattern for ML and MF gestures. Imitation of ML movements should reflect a gradient of complexity from hand/arm movements to finger movements as the biomechanical constraints are more complicated for finger movements than for hand/arm movements. On the contrary, MF gestures are likely to be less taxed by the structural and biomechanical complexity of the movement as they should benefit from being represented in LTM. Such a behavioural prediction also suggests that possible neuroanatomical segregation depending on the body part might emerge in ML but not MF gestures.

At a behavioural level, the main result is the Gesture type \times Body component interaction, indicating that left-brain damaged patients imitated finger ML movements worse than hand/arm ML ones, while no differences between finger and hand/arm MF gestures emerged. Such a different pattern of results is interpreted as MF gestures being retrieved as a whole from LTM, without being broken down into chunks, thus not taxing cognitive resources as ML movements do (see Rumiati and Tessari, 2002, for a detailed dis-

cussion on the role of meaning on motor WM; Tessari and Rumiati, 2004; Tessari et al., 2007). It has been demonstrated that ML movements tax the motor WM system more than MF gestures whose production is facilitated by being already in one's gesture repertoire. In a series of experiments using a dual-task procedure, the existence of a motor short-term/WM system that retains both ML and MF gestures for a limited time was established (Rumiati and Tessari, 2002). We proved that a secondary motor suppression task affected gesture encoding and retention more for ML movements than for MF ones, showing that ML movements were more difficult to encode and retain. Moreover, once learned, ML movements were imitated at the same extent of MF gestures through the semantic route (Tessari et al., 2006). In addition, we showed that a finger motor suppression task interfered more with the encoding of gestures than a hand/arm suppression task ((Tessari and Rumiati, 2002)). The finger suppression task seems to require more cognitive resources than the hand/arm task, leading to reduced motor span. Thus, ML finger movements might be particularly sensitive in differentiating between patients with and without apraxia as the direct route for processing ML movements is more resource-demanding and error-prone than the semantic route for processing MF gestures ((Dovern et al., 2011) Tessari and Rumiati, 2004).

This difference emerged because, at variance with other studies (see (Torraldo et al., 2001)), we controlled for the list composition effect by presenting MF and ML stimuli in separate lists. Indeed, when (finger and hand/arm) MF gestures are presented in the same list, the semantic route is selected; and the (left hemisphere) damage affects imitation of either finger or hand/arm gestures equally, since these gestures are stored in LTM. On the other hand, the imitation of ML movements differed depending on the body part involved, with finger movements being more error-prone than the hand/arm ones, in line with previous evidence (e.g., Achilles et al., 2016). Imitation through the direct route is more resource-demanding (as a decomposi-

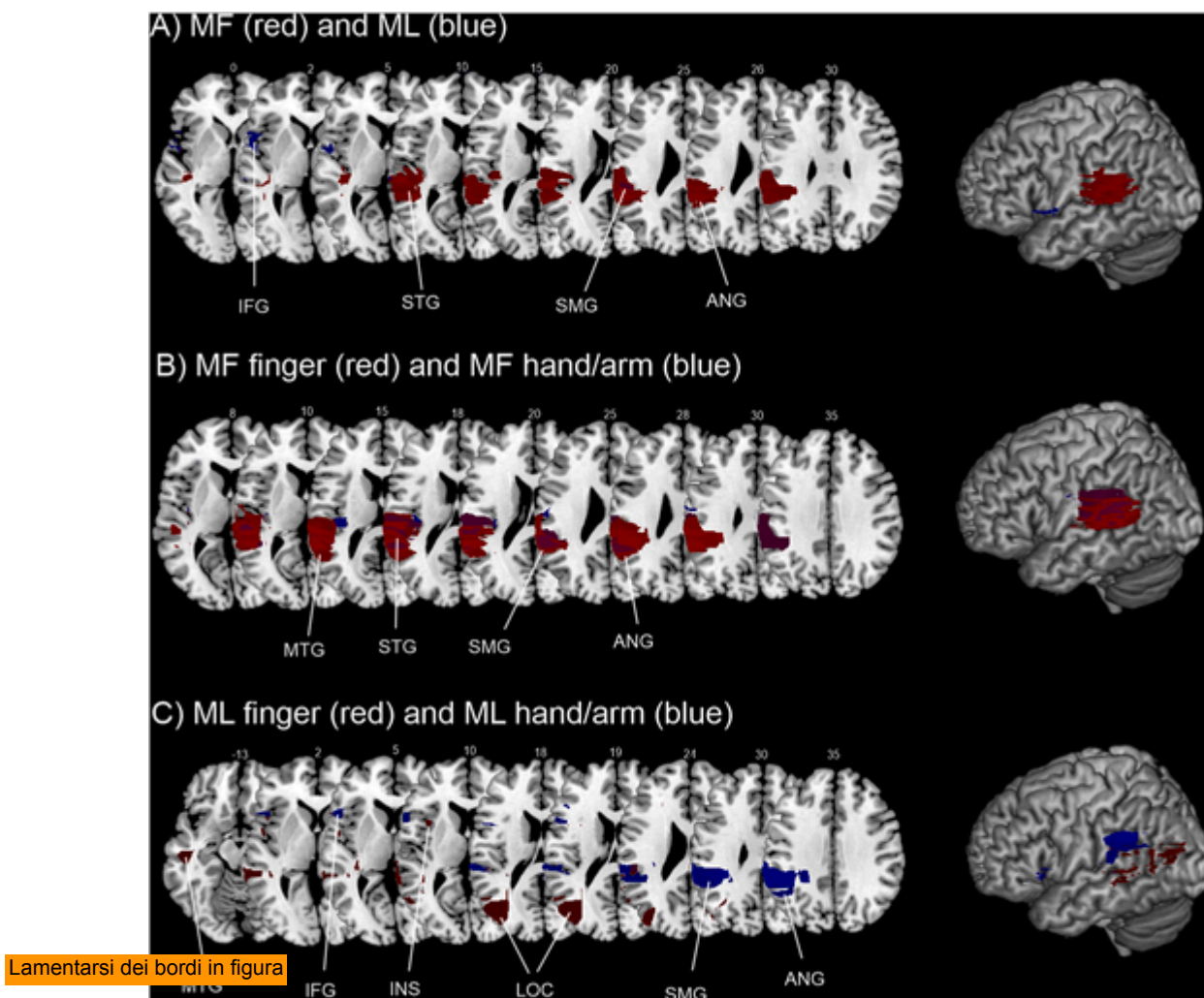


Fig. 4. Results of the subtraction analysis. Regions specifically damaged in the group of patients that presented a deficit in the condition of interest are shown, after subtraction from the group of patients that did not present a deficit in that condition. The subtraction maps for the different types of gestures were then superimposed only for display purposes. A) Subtraction maps for overall MF (in red) and ML gesture imitation (in blue). The overlap between the two conditions is shown in violet. B) Subtraction maps for MF finger (in red) and MF hand/arm gesture imitation (in blue). C) Subtraction maps for ML finger (in red) and ML hand/arm movements imitation (in blue). Only regions lesioned in at least 40% of the patients are shown, only for ML finger movements regions lesioned in at least 25% of the patients are shown. IFG: inferior frontal gyrus; INS: insula; MTG: middle temporal gyrus; superior temporal gyrus; ANG: angular gyrus; SMG: supramarginal gyrus; LOC: lateral occipital cortex. (For interpretation of the references to colour in this figure legend, the reader is referred to the Web version of this article.)

tion/re-composition into elementary motor units is necessary), and finger imitation is likely to engage also visuospatial abilities and a more complex brain network than hand imitation. Goldenberg and Karnath (2006) suggested that finger imitation is more complex than hand/arm postures as it also includes a cognitive component of “selection” of the appropriate elements, involving the IFG as brain region supporting this additional process. According to these authors, finger configurations involve the selection of a limited set of elements that only differ in their serial position. They also found a double dissociation between hand and finger imitation, paired with an anatomical anterior (finger)/posterior (hand) dissociation in left brain-damaged patients. However, a study on a larger sample of patients with left hemisphere lesions did not confirm such an anterior/posterior dissociation but showed instead an association between the dorso-dorsal stream, in particular the inferior and superior parietal lobe, and the overall ability to imitate ML finger and hand/arm gestures (Hoeren et al., 2014).

Likewise, in the present study apraxic patients showed this difficulty gradient in imitation of the two body components, with a worse imitation performance on finger than hand/arm gestures, whereas non-apraxic patients imitated both finger and hand/arm gestures to the same extent. This pattern was probably driven by the ML movements, despite a non-significant triple interaction.

Additionally, apraxic patients' imitation did not differ depending on the meaning of the stimulus (MF and ML), whereas non-apraxic patients imitated MF gestures better than ML movements. Previous studies with both patients and healthy individuals are consistent with the present results, as they show better imitation of MF gestures than ML movements (e.g., Achilles et al., 2016; 2019; Cubelli et al., 2000; Rumiati and Tessari, 2002; Tessari and Rumiati, 2004; Tessari et al., 2007; (Press and Heyes, 2008)). As regards the failure to observe a difference between MF and ML in the apraxic patients, this is not surprising as the ability to imitate and produce MF gestures are often impaired in apraxia (e.g., (Leiguarda and Marsden, 2000)) and brain lesions might affect the two routes at the same time.

The lesion analysis results are generally supportive of the involvement for the ventro-dorsal stream for imitation of MF intransitive gestures, encompassing the inferior parietal lobe, in line with previous evidence (Buxbaum et al., 2014; Dressing et al., 2018; Hoeren et al., 2014; Lesourd et al., 2018; Mengotti et al., 2013; Tessari et al., 2007). The subtraction analysis concerning imitation of ML movements revealed a small overlap with the lesion correlates of imitation of MF gestures in the supramarginal gyrus, suggesting that the ventro-dorsal stream might also support imitation of unknown movements. Whether the ventro-dorsal stream

supports imitation of ML movements is still open to debate, with contrasting findings. Some studies indeed reported the involvement of the inferior parietal lobe in imitation of ML movement (e.g., Buxbaum et al., 2014; Lesourd et al., 2018; Mengotti et al., 2013; Mühlau et al., 2005; Tessari et al., 2007), whereas other studies implicated the dorso-dorsal stream in imitation of ML movements (e.g., Hoeren et al., 2014; (Martin et al., 2016, 2017); Vry et al., 2015). Additionally, imitation of ML movements was associated with the involvement of the inferior frontal gyrus. The IFG has been frequently found to be involved in imitation of gestures, especially in neuroimaging studies (Caspers et al., 2010, for a meta-analysis), as well as in imitation of ML finger postures (Goldenberg and Karnath, 2006). However, the IFG involvement in imitation of MF gestures could also be due to its role of interface between language and action (Weiss et al., 2016) or in processing intransitive MF gestures (in the left hemisphere, see Lesourd et al., 2018, for a recent review).

Regarding the role of the ventral stream, the involvement of the middle temporal gyrus in imitation **blood or BOLD?** is in line with previous neuropsychological observations (e.g., Kalenine, Buxbaum & Coslett, 2010) but also with the higher **blood signal response** to intransitive gestures compared to transitive ones in the middle portion of the left middle temporal gyrus in healthy participants (Papeo et al., 2019). At odds with other studies (e.g., (Dressing et al., 2018); Hoeren et al., 2014; (Martin et al., 2016, 2017); Rijnters et al., 2012; (Rumiati et al., 2005); Tessari et al., 2007; Weiller et al., 2009; 2011), the lesion analysis did not reveal the involvement of the anterior portion of the temporal lobe. Consistently with this finding, we also observed that none of the patients failed to recognize the MF gestures, suggesting that they have a normal ability to extract the meaning from the presented MF gestures whose conceptual representation was intact.

As for specific lesion correlates of finger and hand/arm imitation within MF and ML gestures, lesion analysis associated the poor performance in imitation of finger or hand/arm ML movements with lesions to different regions depending on the body part involved. In contrast, imitation of finger and hand/arm MF gestures seemed to involve the same regions of the inferior parietal lobe, including the supramarginal and angular gyri. Overall, we did not find an anterior/posterior dissociation based on the body part involved in the movement, in contrast with Goldenberg and Karnath (2006), and more in line with other recent studies (Achilles et al., 2017; Hoeren et al., 2014). Focusing on hand/arm gestures, both for MF and ML, an impairment in imitating these gestures seemed to be associated with lesions to similar regions of the inferior parietal lobe, particularly the supramarginal gyrus. Additionally, imitation of hand/arm ML movements seemed to be associated with lesions to the inferior frontal gyrus, at odds with previous literature (e.g., Goldenberg and Karnath, 2006; Tanaka and Inui, 2002). However, the IFG was also found for the subtraction analysis for imitation of overall ML movements, suggesting a more general role of this region, as previously discussed. Impairment in imitation of finger gestures, on the contrary, seemed to be associated with a more diverse network, not only encompassing the inferior parietal lobe for MF gestures, but also lateral occipital regions for ML movements. This result is generally supportive of the hypothesis of finger gestures as being intrinsically more complex for imitation, with the semantic aspect of imitation (MF gestures) coded in the ventro-dorsal stream, and further non-semantic aspects processed elsewhere, possibly in the inferior frontal gyrus and in the dorso-dorsal system as shown in previous studies (Goldenberg and Karnath, 2006; Hoeren et al., 2014; Achilles et al., 2019), or in occipito-temporal regions, such as the **togliere il ;** occipital cortex (LOC), as suggested by the present results. The LOC is a high-order visual area usually involved in object recognition (Grill-Spector et al., 1999; Larsson and Heeger, 2006). The need for visual processing of complex stimuli such as finger configurations might explain this region's involvement. The temporo-occipital cortex has been reported in patients as a lesion correlate of imitation of both ML movements as well as pantomimes (Hoeren et al., 2014), as well as in healthy participants as neural correlates of ML movements imitation (Rumiati et al.,

2005). This region is possibly forwarding higher-order visual information to the parietal lobe for imitation processing.

To conclude, the present results enrich the extant knowledge on imitation. By investigating both the effects of body-part specificity and meaning in apraxic and non-apraxic patients, we were able to show how the body-part does not modulate imitation of MF gestures. In contrast, a different pattern is observed for ML movements, with reduced imitation of those involving finger configurations. In addition, the present results support the importance of considering not only gesture meaning and body-part specificity, but also gesture list composition, in studies investigating imitation in patients, and apraxia particularly. Thus, controlling for list composition must become a methodological requirement for future studies.

5. Conclusion

In the present study, we demonstrated that finger and hand/arm movements were differentially processed in imitation of ML movements, **toglierei il "the"** of MF gestures showed no such dissociation. This is in line with the existing cognitive theories of the dual routes of gesture imitation: in the imitation of MF gestures, the primary role is played by the stored motor representations in LTM recalled as meaningful chunks, independently of the body part involved in the movement; on the contrary, when ML movements are imitated, the direct route of visuomotor conversion is used, including body-part specific mechanisms.

Credit author statement

A.T.: Conceptualization, Methodology, Formal analysis, Data curation, Writing- Original draft preparation; Writing- Reviewing and Editing; Supervision; Funding acquisition; **P.M.:** Formal analysis, Data curation, Writing- Original draft preparation; Writing- Reviewing and Editing; Visualization; **L.F.:** Data curation; **G.T.:** Funding, Supervision; **S.B.:** Investigation; **M.T.:** Resources; Supervision; **R.I.R.:** Writing- Reviewing and Editing.

Declaration of competing interest

The authors report no competing interests.

Acknowledgment

This study was supported by a grant from the Fondazione Cassa di Risparmio di Bologna (n.2005/2445), in which AT and GT were involved.

Appendix.

List of then meaningful and meaningless gestures used in the test (for the Italian culture). In the brackets a "F" indicates the case of gestures with a main finger component and "H/A" the case of a gesture with a main hand/arm component.

MEANINGFUL (MF) GESTURES

01. I am tired/I go to sleep (H/A).
02. Military salute (H/A).
03. I am hungry (H/A).
04. No! (F).
05. Hallo (F).
06. Later (F).
07. Silence! (H/A).
08. Crazy (H/A).
09. Stop! (H/A).
10. Well done (F).
11. Come here! (F).
12. Finger crossed (F).
13. Hitch-hiking (H/A).
14. Listening (H/A).
15. Strength (H/A).

16. So-and-so/more or less (F).
17. Go away (F).
18. Victory (F).

MEANINGLESS (ML) GESTURES

01. Horizontal palm up on the abdomen (H/A).
02. Horizontal back hand under the chin (H/A).
03. Hand over the opposite shoulder (H/A).
04. Pinkie straight down (F).
05. Thumb close the middle finger (F).
06. Closed fist with the palm up and the thumb pointing outward (F).
07. Back of the hand horizontally placed on the eyes (H/A).
08. Back of the hand on the contralateral cheek (H/A).
09. Palm of the hand on the nape (H/A).
10. Extended thumb and pinkie, other fingers closed in a fist and hand positioned with the back toward the observer (F).
11. Horizontal hand with the middle finger over the index finger (F).
12. Fist with the thumb extended toward the body midline (F).
13. Palm of the hand on the ipsilateral shoulder (H/A).
14. Palm of the hand toward the observer and positioned perpendicularly over the head (H/A).
15. Back of the hand toward the observer, hand upright with the top of the finger under the chin (H/A).
16. Hand closed in a fist, with the back toward the observer and positioned over the pinkie with the index finger pointing toward the body midline (F).
17. Back of the hand toward the observer and hand lying on the pinkie side with the thumb closed to the index finger (F).
18. Hand closed around the thumb in a fist (F).

Uncited references

Martin et al. (2017); Toraldo et al. (2001).

References

- Achilles, E.I.S., Fink, G.R., Fischer, M.H., Dovern, A., Held, A., Timpert, D.C., et al., 2016. Effect of meaning on apraxic finger imitation deficits. *Neuropsychologia* 82, 74–83.
- Achilles, E.I., Weiss, P.H., Fink, G.R., Binder, E., Price, C.J., Hope, T.M., 2017. Using multi-level Bayesian lesion-symptom mapping to probe the body-part-specificity of gesture imitation skills. *Neuroimage* 161, 94–103.
- Achilles, E.I., Ballweg, C.S., Niessen, E., Kusch, M., Ant, J.M., Fink, G.R., Weiss, P.H., 2019. Neural correlates of differential finger gesture imitation deficits in left hemisphere stroke. *Neuroimage: Clinical* 23, 101915.
- Bartolo, A., Cubelli, R., Della Sala, S., Drei, S., e Marchetti, C., 2001. Double dissociation between meaningful and meaningless gesture production in apraxia. *Cortex* 37, 696–699.
- Basso, A., Luzzatti, C., Spinnler, H., 1980. Is ideomotor apraxia the outcome of damage to well-defined regions of the left hemisphere? Neuropsychological study of CAT correlation. *J. Neurol. Neurosurg. Psychiatr.* 43 (2), 118–126.
- Binkofski, F., Buxbaum, L.J., 2013. Two action systems in the human brain. *Brain Lang.* 127 (2), 222–229.
- Bonivento, C., Rumiati, R.I., Biasutti, E., Humphreys, G.W., 2013. The role of the basal ganglia in action imitation: neuropsychological evidence from Parkinson's disease patients. *Exp. Brain Res.* 224 (2), 211–220.
- Buxbaum, L.J., Randerath, J., 2018. Limb apraxia and the left parietal lobe. In: *Handbook of Clinical Neurology*, 151. Elsevier, pp. 349–363.
- Buxbaum, L.J., Shapiro, A.D., Coslett, H.B., 2014. Critical brain regions for tool-related and imitative actions: a componential analysis. *Brain* 137 (7), 1971–1985.
- Carlesimo, G.A., Caltagirone, C., Gainotti, G.U.I.D., Fadda, L., Gallassi, R., Lorusso, S., et al., 1996. The mental deterioration battery: normative data, diagnostic reliability and qualitative analyses of cognitive impairment. *Eur. Neurol.* 36 (6), 378–384.
- Carmo, J.C., Rumiati, R.I., 2009. Imitation of transitive and intransitive actions in healthy individuals. *Brain Cognit.* 69 (3), 460–464.
- Caspers, S., Zilles, K., Laird, A.R., Eickhoff, S.B., 2010. ALE meta-analysis of action observation and imitation in the human brain. *Neuroimage* 50 (3), 1148–1167.
- Crawford, J.R., Garthwaite, P.H., 2005. Testing for suspected impairments and dissociations in single-case studies in neuropsychology: evaluation of alternatives using Monte Carlo simulations and revised tests for dissociations. *Neuropsychology* 19 (3), 318.
- Cubelli, R., Marchetti, C., Boscolo, G., e Della Sala, S., 2000. Cognition in action: testing a model of limb apraxia. *Brain Cognit.* 44, 144–165.
- Cubelli, R., Bartolo, A., Nichelli, P., Della Sala, S., 2006. List effect in apraxia assessment. *Neurosci. Lett.* 407 (2), 118–120.
- de Haan, B., Karnath, H.O., 2018. A hitchhiker's guide to lesion-behaviour mapping. *Neuropsychologia* 115, 5–16.
- De Renzi, E., Faglioni, P., 1999. Apraxia. In: Denes, G., Pizzamiglio, L. (Eds.), *Handbook of Clinical and Experimental Neuropsychology*. Psychology Press, Hove, pp. 421–440.
- De Renzi, E., Motti, F., Nichelli, P., 1980. Imitating gestures: a quantitative approach to ideomotor apraxia. *Arch. Neurol.* 37 (1), 6–10.
- Dovern, A., Fink, G.R., Saliger, J., Karbe, H., Koch, I., Weiss, P.H., 2011. Apraxia impairs intentional retrieval of incidentally acquired motor knowledge. *J. Neurosci.* 31 (22), 8102–8108.
- Dressing, A., Nitschke, K., Kümmerer, D., Bormann, T., Beume, L., Schmidt, C.S., Kaller, C.P., 2018. Distinct contributions of dorsal and ventral streams to imitation of tool-use and communicative gestures. *Cerebr. Cortex* 28 (2), 474–492.
- Geschwind, N., 1965. Disconnexion syndromes in animal and man. *Brain* 88, 585–644.
- Giovagnoli, A.R., Del Pesce, M., Mascheroni, S., Simoncelli, M., Laiacina, M., Capitani, E., 1996. Trail making test: normative values from 287 normal adult controls. *Ital. J. Neurol. Sci.* 17 (4), 305–309.
- Goldenberg, G., 1999. Matching and imitation of hand and finger postures in patients with damage in the left or right hemispheres. *Neuropsychologia* 37 (5), 559–566.
- Goldenberg, G., 2001. Imitation and matching of hand and finger postures. *Neuroimage* 14 (1), S132–S136.
- Goldenberg, G., Hagmann, S., 1997. The meaning of meaningless gestures: a study of visuo-imitative apraxia. *Neuropsychologia* 35 (3), 333–341.
- Goldenberg, G., Karnath, H.O., 2006. The neural basis of imitation is body part specific. *J. Neurosci.* 26 (23), 6282–6287.
- Goldenberg, G., Randerath, J., 2015. Shared neural substrates of apraxia and aphasia. *Neuropsychologia* 75, 40–49.
- Goldenberg, G., Strauss, S., 2002. Hemisphere asymmetries for imitation of novel gestures. *Neurology* 59 (6), 893–897.
- Grill-Spector, K., Kushnir, T., Edelman, S., Avidan, G., Itzhak, Y., Malach, R., 1999. Differential processing of objects under various viewing conditions in the human lateral occipital complex. *Neuron* 24 (1), 187–203.
- Hoeren, M., Kümmerer, D., Bormann, T., Beume, L., Ludwig, V.M., Vry, M.S., Weiller, C., 2014. Neural bases of imitation and pantomime in acute stroke patients: distinct streams for praxis. *Brain* 137 (10), 2796–2810.
- Jeannerod, M., Decety, J., Michel, F., 1994. Impairment of grasping movements following a bilateral posterior parietal lesion. *Neuropsychologia* 32 (4), 369–380.
- Kalénine, S., Buxbaum, L.J., Coslett, H.B., 2010. Critical brain regions for action recognition: lesion symptom mapping in left hemisphere stroke. *Brain* 133 (11), 3269–3280.
- Larsson, J., Heeger, D.J., 2006. Two retinotopic visual areas in human lateral occipital cortex. *J. Neurosci.* 26 (51), 13128–13142.
- Leiguarda, R., 2001. Limb apraxia: cortical or subcortical. *Neuroimage* 14 (1), S137–S141.
- Leiguarda, R., Marsden, C. D., 2000. Limb apraxias: higher-order disorders of sensorimotor integration. *Brain* 123 (5), 860–879.
- Lesourd, M., Osiurak, F., Baumard, J., Bartolo, A., Vanbellingen, T., Reynaud, E., 2018. Cerebral correlates of intransitive gestures: an integrative review of neuroimaging data and brain lesion studies. *Neurosci. Biobehav. Rev.* 95, 44–60.
- Luzzatti, C., Willmes, K., De Bleser, R., 1996. Aachen Aphasia Test (AAT)-versione Italiana. *Organizzazioni Speciali*, Firenze.
- Martin, M., Beume, L., Kümmerer, D., Schmidt, C.S., Bormann, T., Dressing, A., et al., 2016. Differential roles of ventral and dorsal streams for conceptual and production-related components of tool use in acute stroke patients. *Cerebr. Cortex* 26 (9), 3754–3771.
- Martin, M., Dressing, A., Bormann, T., Schmidt, C.S., Kümmerer, D., Beume, L., et al., 2017. Componential network for the recognition of tool-associated actions: evidence from voxel-based lesion-symptom mapping in acute stroke patients. *Cerebr. Cortex* 27 (8), 4139–4152.
- Mengotti, P., Corradi-Dell'Acqua, C., Negri, G.A., Ukmair, M., Pesavento, V., Rumiati, R.I., 2013. Selective imitation impairments differentially interact with language processing. *Brain* 136 (8), 2602–2618.
- Mengotti, P., Ripamonti, E., Pesavento, V., Rumiati, R.I., 2015. Anatomical and spatial matching in imitation: evidence from left and right brain-damaged patients. *Neuropsychologia* 79, 256–271.
- Mühlau, M., Hermsdörfer, J., Goldenberg, G., Wohlschläger, A.M., Castrop, F., Stahl, R., et al., 2005. Left inferior parietal dominance in gesture imitation: an fMRI study. *Neuropsychologia* 43 (7), 1086–1098.
- Orsini, A., Grossi, D., Capitani, E., Laiacina, M., Papagno, C., Vallar, G., 1987. Verbal and spatial immediate memory span: normative data from 1355 adults and 1112 children. *Ital. J. Neurol. Sci.* 8 (6), 537–548.
- Papeo, L., Agostini, B., Lingnau, A., 2019. The Large-Scale organization of gestures and words in the middle temporal gyrus. *J. Neurosci.* 39 (30), 5966–5974.
- Peigneux, P., Van der Linden, M., Garraux, G., Laureys, S., Degueldre, C., Aerts, J., et al., 2004. Imaging a cognitive model of apraxia: the neural substrate of gesture-specific cognitive processes. *Hum. Brain Mapp.* 21 (3), 119–142.
- Poizner, H., Mack, L., Verfaellie, M., Rothi, L.J.G., Heilman, K.M., 1990. Three-dimensional computergraphic analysis of apraxia: neural representations of learned movement. *Brain* 113 (1), 85–101.
- Press, C., Heyes, C., 2008. Stimulus-driven selection of routes to imitation. *Exp. Brain Res.* 188 (1), 147.
- Ray, E., Heyes, C., 2011. Imitation in infancy: the wealth of the stimulus. *Dev. Sci.* 14, 92–105.
- Rijntjes, M., Weiller, C., Bormann, T., Musso, M., 2012. The dual loop model: its relation to language and other modalities. *Front. Evol. Neurosci.* 4, 9.
- Rorden, C., Karnath, H.O., 2004. Using human brain lesions to infer function: a relic from a past era in the fMRI age? *Nat. Rev. Neurosci.* 5 (10), 812.
- Rorden, C., Karnath, H.O., Bonilha, L., 2007. Improving lesion-symptom mapping. *J. Cognit. Neurosci.* 19 (7), 1081–1088.
- Rothi, L.J.G., Heilman, K.M., 1985. Ideomotor apraxia: gestural discrimination, comprehension and memory. In: *Advances in Psychology*, 23. pp. 65–74 (North-Holland).
- Rothi, L.J.G., Ochipa, C., e Heilman, K.M., 1991. A cognitive neuropsychological model of limb praxis. *Cogn. Neuropsychol.* 8, 443–458.
- Rumiati, R.I., Bekkering, H., 2003. To imitate or not to imitate? How the brain can do it, that is the question!. *Brain Cognit.* 53 (3), 479–482.

- Rumiati, R.I., Tessari, A., 2002. Imitation of novel and well-known actions: the role of short-term memory. *Exp. Brain Res.* 142, 425–433.
- Rumiati, R.I., Weiss, P.H., Tessari, A., Assmus, A., Zilles, K., Herzog, H., Fink, G.R., 2005. Common and differential neural mechanisms supporting imitation of meaningful and meaningless actions. *J. Cognit. Neurosci.* 17 (9), 1420–1431.
- Sebastianutto, L., Mengotti, P., Spiezio, C., Rumiati, R.I., Balaban, E., 2017. Dual-route imitation in preschool children. *Acta Psychol.* 173, 94–100.
- Shallice, T., Venable, N., Rumiati, R.I., 2005. Dissociable distal and proximal motor components: evidence from perseverative errors in three apraxic patients. *Cogn. Neuropsychol.* 22 (5), 625–639.
- Sirigu, A., Grafman, J., Bressler, K., Sunderland, T., 1991. Multiple representations contribute to body knowledge processing: evidence from a case of autotopagnosia. *Brain* 114 (1), 629–642.
- Sirigu, A., Cohen, L., Duhamel, J.R., Pillon, B., Dubois, B., Agid, Y., 1995. A selective impairment of hand posture for object utilization in apraxia. *Cortex* 31 (1), 41–55.
- Spinnler, H., Tognoni, G., 1987. Standardizzazione e taratura italiana di test neuropsicologici. Italian standardization and validation neuropsychological tests. *Ital. J. Neurol. Sci.* 6 (Suppl. 8), 1–20.
- Tanaka, S., Inui, T., 2002. Cortical involvement for action imitation of hand/arm postures versus finger configurations: an fMRI study. *Neuroreport* 13 (13), 1599–1602.
- Tanaka, S., Inui, T., Iwaki, S., Konishi, J., Nakai, T., 2001. Neural substrates involved in imitating finger configurations: an fMRI study. *Neuroreport* 12 (6), 1171–1174.
- Tessari, A., Cubelli, R., 2014. Route selection in action imitation: a matter of strategic choice? *Cortex* 57, 277–278.
- Tessari, A., Rumiati, R.I., 2002. Motor distal component and pragmatic representation of objects. *Cognitive Brain Research* 14 (2), 218–227.
- Tessari, A., Rumiati, R.I., 2004. The strategic control of multiple routes in imitation of actions. *J. Exp. Psychol. Hum. Percept. Perform.* 30, 1107–1116.
- Tessari, A., Bosanac, D., Rumiati, R.I., 2006. Effect of learning on imitation of new actions: implications for a memory model. *Exp. Brain Res.* 173 (3), 507–513.
- Tessari, A., Canessa, N., Ukmar, M., Rumiati, R.I., 2007. Neuropsychological evidence for a strategic control of multiple routes in imitation. *Brain* 130 (4), 1111–1126.
- Tessari, A., Toraldo, A., Lunardelli, A., Zadini, A., Rumiati, R.I., 2015. STIMA: a short screening test for ideo-motor apraxia, selective for action meaning and bodily district. *Neurol. Sci.* 36 (6), 977–984.
- Tomasello, M., Savage-Rumbaugh, S., Kruger, A.C., 1993. Imitative learning of actions on objects by children, chimpanzees, and enculturated chimpanzees. *Child Dev.* 64, 1688–1705.
- Toraldo, A., Reverberi, C., Rumiati, R.I., 2001. Critical dimensions affecting imitation performance of patients with ideomotor apraxia. *Cortex* 37 (5), 737–740.
- Vry, M.S., Tritschler, L.C., Hamzei, F., et al., 2015. The ventral fiber pathway for pantomime of object use. *Neuroimage* 106, 252–263.
- Warrington, E.K., James, M., 1991. *The Visual Object and Space Perception Battery*. Thames Valley Test Company, Bury St Edmunds, UK.
- Weiller, C., Musso, M., Rijntjes, M., Saur, D., 2009. Please don't underestimate the ventral pathway in language. *Trends Cognit. Sci.* 13 (9), 369.
- Weiller, C., Bormann, T., Saur, D., Musso, M., Rijntjes, M., 2011. How the ventral pathway got lost—And what its recovery might mean. *Brain Lang.* 118 (1–2), 29–39.
- Weiss, P.H., Rahbari, N.N., Hesse, M.D., Fink, G.R., 2008. Deficient sequencing of pantomimes in apraxia. *Neurology* 70 (11), 834–840.
- Weiss, P.H., Ubben, S.D., Kaesberg, S., Kalbe, E., Kessler, J., Liebig, T., Fink, G.R., 2016. Where language meets meaningful action: a combined behavior and lesion analysis of aphasia and apraxia. *Brain Struct. Funct.* 221 (1), 563–576.